

PRESENTACIÓN DE CASO CLINICO

**SERVICIO DE ENDOCRINOLOGIA
Hospital Nacional Guillermo Almenara Irigoyen
Abril 2016**

HISTORIA CLÍNICA

- **FILIACIÓN**

- Nombre: S. O. N.
- Edad: 44 años
- Raza: Mestizo
- Sexo: M
- Ocupación: Obrero
- Procedencia: SJL, LIMA

ANTECEDENTES

- **Antecedentes Patológicos**

- 2012 Asma Bronquial.

- **Antecedentes Familiares**

- Padre: fallecido por NM de próstata
- Madre: Viva, aparentemente sana
- Hermanos: 07 vivos, aparentemente sanos
- Hijos: 01 aparentemente sana.
- Abuelos: 04 fallecidos desconoce la causa.

- **Antecedentes Fisiológicos**

- Nacimiento Domiciliario.
- DPM Aparentemente Normal

- **Medicación Habitual**

- Niega

- **Hospitalizaciones previas**

- 1999 Traumatismo Abdominal
- 2003 Tumoración en Pulmonar
- Nov 2014 Oncología por tumor hepático.
- Enero 2015 Oncología por Biopsia Hepática.
- Febrero 2015 Oncología por Biopsia Hepática.

2004

- Tos crónica = 3-4m
- Rasgos hemoptoicos
- Rx Tórax
- Quiste Pulmón



OCHO meses después

- Neumología
- TAC Tórax-Abd
- Imagen tumoral
- Broncofibroscopía



- Biopsia ???
- Adenectomía
- Pulmón Derecho



Enero 2014

- Diarrea
- Espontánea
- Acuosa. s/moco, sangre
- Vol. 200cc/cámara
- Dolor tipo cólico



Nov. 14'

- Oncología
- 02 BIPA – TAC (-)
- Lap. Exp. Biopsia
- Cromogranina (+)
- Synaptofisina (+)



Setiembre 14'

- Gastroent.
- Colonoscopia
- Lesión subped.
- TAC Abdomen
- Múltiples Lesiones hepáticas



- Dura 04d
- Intervalo 2-3ss
- Dispepsia alimentos grasos
- Flatulencia y sensación nauseosa



ENDOCRINOLOGIA

RELATO

Apetito

- CONSERVADO

Sed

- CONSERVADO

Orina

- Conservado. NO historia de LITIASIS

Deposiciones

- ACUOSAS intermitentes 2-3ss. Dolor abdominal

Sueño

- Disminuído 04h/d

Peso

- BAJA de peso 10K en 01 año

Funciones Vitales

PA 110/80mmHg

FC 82x'

FR 18x'

W 54kg

Talla 164cm

IMC 20.08Kg/m²

P. Abd. 74cm



Refiere

- Diarrea intermitente
- Crónica + dolor abdominal
- Baja Ponderal importante
- Antecedente tumor Pulmonar

Tumores Neuroendocrinos

NO se Registra

- Flushing
- Diaforesis
- Broncoespasmo
- Hipotensión + palpitaciones
- Epigastralgia urente
- Hipoglicemia
- Ictericia



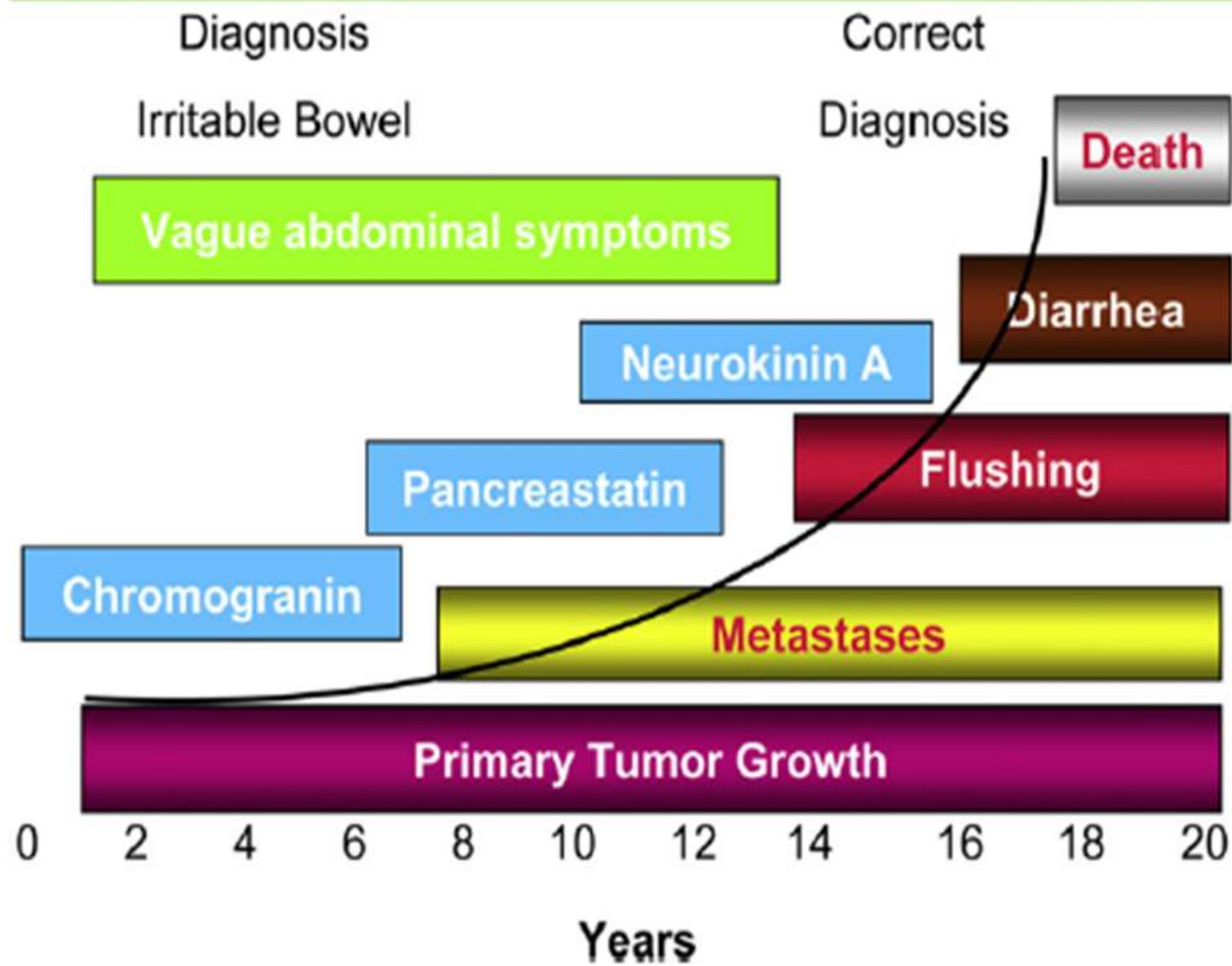
-

Table 1
Clinical presentations, syndromes, tumor types, sites, and hormones⁴

Clinical Presentation	Syndrome	Tumor Type	Sites	Hormones
Flushing	Carcinoid Medullary carcinoma of thyroid Pheochromocytoma	Carcinoid C-cell tumor Tumor of chromaffin cells	Mid/foregut adrenal medulla gastric Thyroid C cells Adrenal and sympathetic nervous system	Serotonin, CGRP, calcitonin Metanephrine and normetanephrine
Diarrhea, abdominal pain, and dyspepsia	Carcinoid, WDHA, ZE, PP, MCT	Carcinoid, VIPoma, gastrinoma, PPoma, medullary carcinoma thyroid, mastocytoma	As above, pancreas, mast cells, thyroid	As above, VIP, gastrin, PP, calcitonin
Diarrhea/steatorrhea	Somatostatin Bleeding GI tract	Somatostatinoma, neurofibromatosis	Pancreas Duodenum	Somatostatin
Wheezing	Carcinoid	Carcinoid	Gut/pancreas/lung	SP, CGRP, serotonin
Ulcer/dyspepsia	Zollinger-Ellison	Gastrinoma	Pancreas/duodenum	Gastrin
Hypoglycemia	Whipple's triad	Insulinoma, sarcoma, hepatoma	Pancreas, retroperitoneal liver	Insulin, IGF-1, IGF-11
Dermatitis	Sweet syndrome Pellagra	Glucagonoma Carcinoid	Pancreas Midgut	Glucagon Serotonin
Dementia	Sweet syndrome	Glucagonoma	Pancreas	Glucagon
Diabetes	Glucagonoma Somatostatin	Glucagonoma Somatostatinoma	Pancreas Pancreas	Glucagon Somatostatin
DVT, steatorrhea, cholelithiasis, neurofibromatosis	Somatostatin	Somatostatinoma	Pancreas Duodenum	Somatostatin
Silent, liver metastases	Silent	PPOMA	Pancreas	PP

Abbreviations: CGRP, calcitonin gene-related peptide; PP, pancreatic polypeptide; IGF, insulin-like growth factor; VIP, vasoactive intestinal peptide; MCT, medullary carcinoma of thyroid; SP, substance P.

Data from Vinik A, O'Dorisio T, Woltering E, et al. Neuroendocrine tumors: a comprehensive guide to diagnosis and management. 1st edition. Inglewood (CA): Interscience Institute; 2006.



The natural history of carcinoid tumors.

EXÁMENES AUXILIARES

Hemograma	11 Marzo 15'
Leuc	5090
Eritrocitos	4.84mill
Hb	11.1
Eosinofilos	2.2
Linfocitos	14
Basófilos	0.7
Monocitos	4.7
Segmen.	77.5

	11 Marzo 2015
Fosfatasa Alcalina	153 U/L
TGP/ALAT	32 U/L
TGO/ASAT	29 U/L
GGTP	67 U/L
Bilirub. Total	0.32 m/dl
Prot. Total	6.5 g/dl
Albúmina	3.7 g/dl
Globulina	2.8

	11 Marzo 2015
Sodio	140.7 mmol/L
Potasio	3.65 mmol/L
Cloro	103.4 mmol/L

EXÁMENES AUXILIARES

	11 Marzo 2015
Glicemia	109 mg/dl
Creatinina	0.7 mg/dl
Urea	17.33 mg/dl
TFG	130.21 ml/m

	11 Marzo 2015
Calcio Total	9.4 mg/dl
Fósforo	3 mg/dl
PTH	3.13 pg/ml

	11 marzo 2015
Calcitonina	> 2000 pg/ml
Test Alfa – Fetoproteína	3.4 ng/ml
Test Carcino Embrionario	1.32 ng/ml
Cortisol	10.8 ug/dl
ACTH	10.5 pg/ml
TSH	1.37 uUI/ml

REVIEW

**HYPERCALCAEMIA IS NOT PATHOGNOMONIC
OF MEDULLARY THYROID CARCINOMA**

**Sergio PA Toledo,¹ Delmar M Lourenço Jr,¹ Marcelo Augusto Santos,¹ Marcos R
Tavares,^{II} Rodrigo A Toledo,¹ Joya Emilie de Menezes Correia-Deur¹**

doi: 10.1590/S1807-59322009000700015

Table 1- Hypercalcitoninemia in non-medullary thyroid carcinoma conditions

Physiologic conditions ^{2,35,36}	Sex Age Physical activity
Drugs ^{2, 29,32}	Omeprazole and similar drugs (interfere with the H ⁺ pump) Glucocorticoids Beta-blockers Glucagon CGRP Enteroglucagon Pancreozimine
Non-thyroid pathologies ^{2-4,5,28,29,34}	Hypergastrinemias Hypercalcemias (hyperparathyroidism) Renal insufficiency Neuroendocrine tumors: pheochromocytoma paraganglioma enteropancreatic endocrine tumors VIPoma insulinomacarcinoids small cell pulmonary tumor
Thyroid pathologies ^{2,9,20,36,38,39,40}	Thyroid carcinomas: follicular carcinoma papillary carcinoma Chronic autoimmune thyroiditis*

* There is some debate on this subject (see text)

Table 2 - Calcitonin values and risk for medullary thyroid carcinoma*

Value (pg/ml)	Risk for MTC
>100	Extremely high (100%)
≥ 50 and < 100**	Moderate (25%)
≥ 20 and < 50**	Low (8.3%)
<8.5 for men/<5.0 for women	Normal

* Based on Constante et al., 2007. ** It is recommended to systematically investigate non-MTC conditions in patients with calcitonin levels in these ranges.

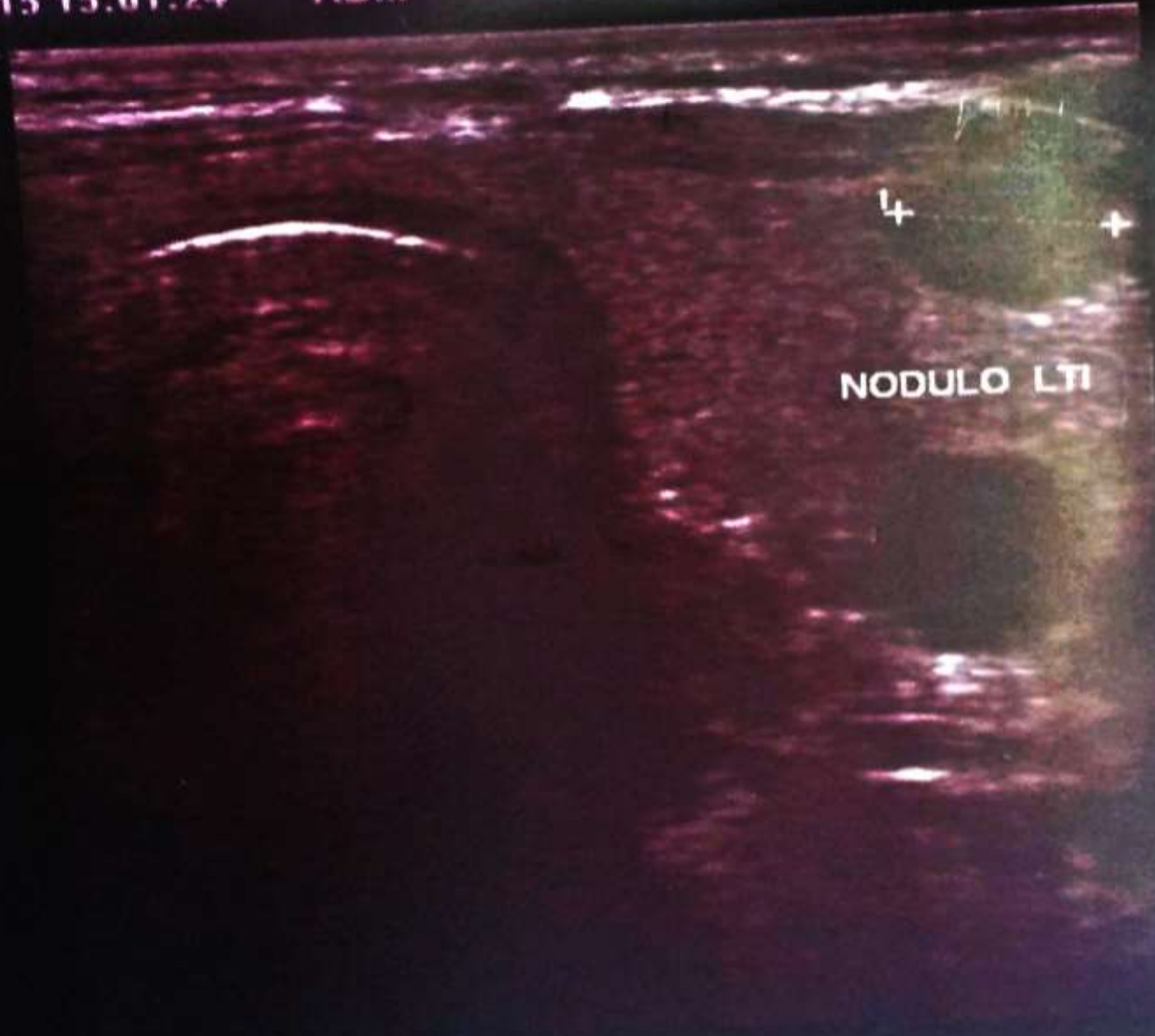ECOGRAFÍA CERVICAL

- LTD: Homogéneo de aspecto morfológico y tamaño conservado, no lesiones focales ni quísticas. Mide 31x14x17mm
- LTI: mide 30x13x16mm. Aspecto heterogéneo, **con presencia de lesión nodular hipoecogénica de 7mm**, adyacente a cara anterior bilateral.

16 Marzo 2015

IOSEP, G. ALMENARA EsS:
16/03/15 15:01:24 ADM

CF



NODULO LTI



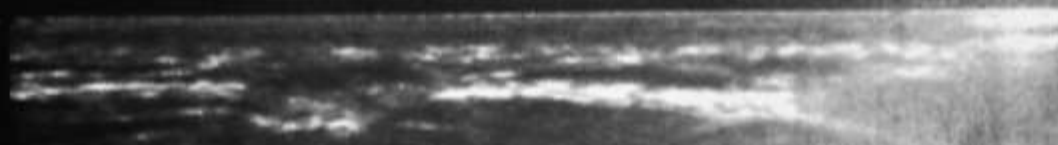
HOSP. G. ALMENARA EsS2

16/03/15 15:00:57 ADM

MI 1.0 TIs 0.0 17L

Tiroides

B
Frec 10.0 MHz
Gn 38
E/A 1/4
Mapa C/M/D
D 4.0 cm
DR 72
FR 21 Hz
AO 100 %



NODULO LTI

2-

3-

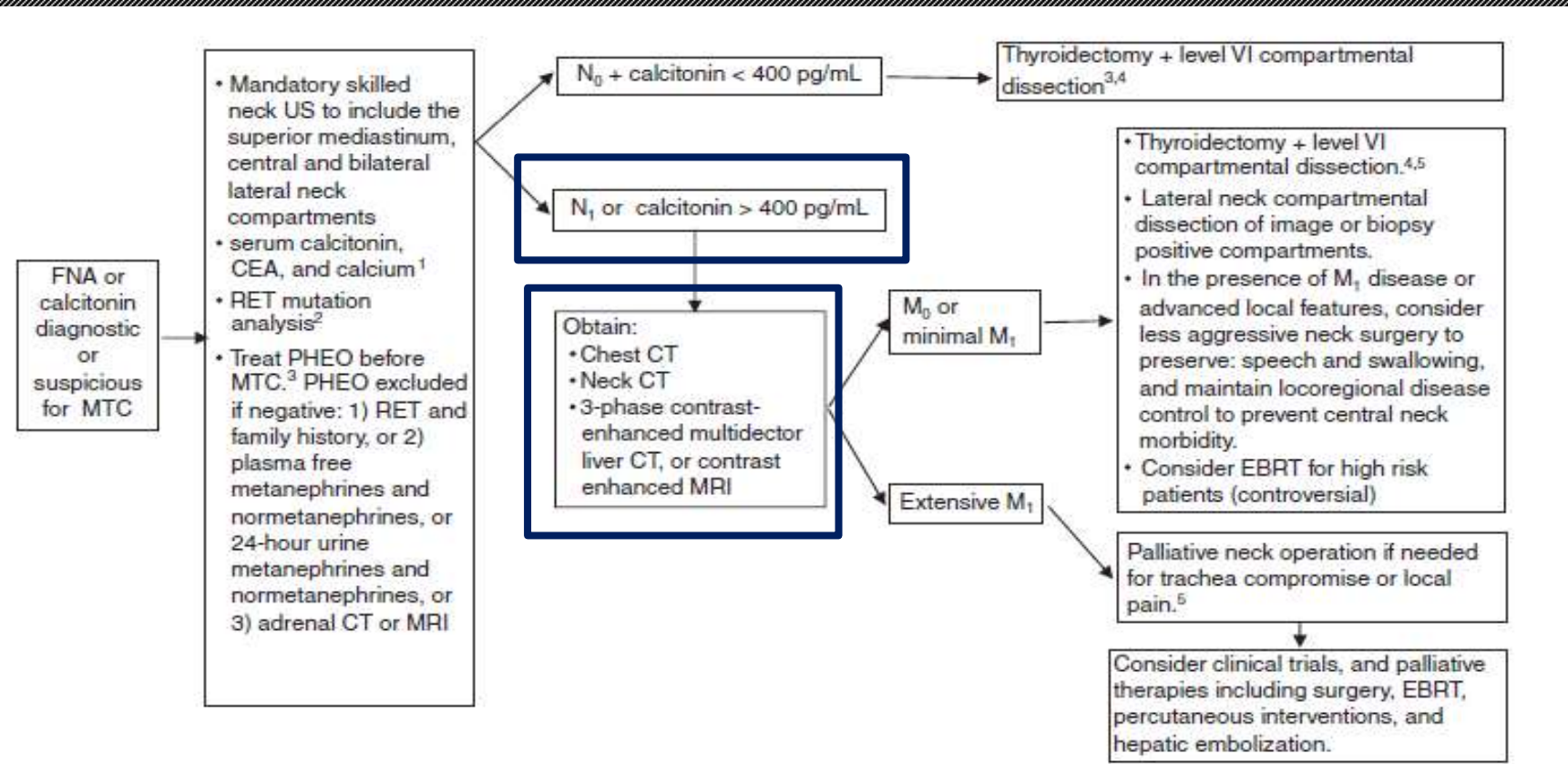
4-

CITOLOGIA

- Tipo de Muestra: Tiroides
- Resultado:
- Compatible con Carcinoma Medular Tiroides

24 Marzo 2015

	CMT esporádico	CMT hereditario
Mutaciones somáticas	+	-
Mutaciones de la línea germinal	- 6 - 7 %	+
Focalidad	Unifocal 20% (multifocal)	Multifocal
Edad de presentación	4ta década	Diferentes tipos de edad
Asociaciones	-	Feocromocitoma Hiperparatiroidismo
Metástasis	Ganglios cervicales y/o mediastino Hígado Pulmón Óseo (líticas)	Ganglionar 2da década



¹Treat hyperparathyroidism with 4 gland resection and autograft to heterotopic site, or subtotal parathyroidectomy. Consider cryopreservation.

²Ideally performed with genetics counseling and completed preoperatively.

³PHEO preoperative screening should begin by age 8 years for MEN 2B and mutated *RET* codons 634 and 630; and by age 20 years for other *RET* mutations.

⁴Parathyroid glands resected or devascularized should be autografted in the neck in *RET*-negative, MEN 2B, and FMTC patients, while MEN 2A glands should be autografted to a heterotopic site.

⁵Consider external beam radiation of TNM stage T4 disease to prevent recurrent local disease.

FNA, fine-needle aspiration biopsy.

FIG. 2. Initial diagnosis and therapy of clinically apparent disease.

Somatic mutations in the *RET* proto-oncogene in sporadic medullary thyroid carcinomas

S. Dvorakova^{a,*}, E. Vaclavikova^a, V. Sykorova^a, J. Vcelak^a, Z. Novak^b, J. Dusko^c,
A. Ryska^d, J. Laco^d, J. Cap^e, D. Kodetova^f, R. Kodet^f, L. Krskova^f, P. Vlcek^g, J. Astl^h,
D. Vesely^h, B. Bendlova^a

Table 2

Detection rate of the *RET* proto-oncogene somatic mutations

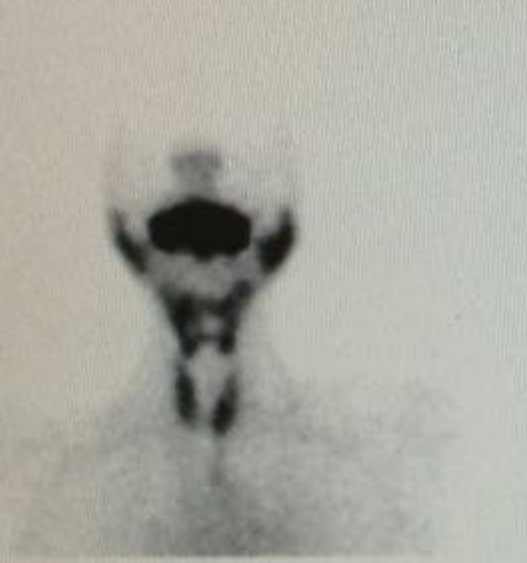Type of mutation		number	%	% of mutations
exon 16	Met918Thr	13	27.1	43.4
	Thr930Met	1	2	
	Ser922Pro	1	2	
	Gly911Asp, Met918Thr, Glu921Lys	1	2	
exon 10+16	Val591Ile, Met918Thr	1	2	
exon 11	Cys630Arg	1	2	
	del 6bp 632-633	3	6.1	
exon 15	Ala883Phe	1	2	
	Ala883Ser	1	2	
total with mutation		23	47.9	
total no mutation		25	52.1	
total tumors		48	100	

GAMMAGRAFÍA 99-TC

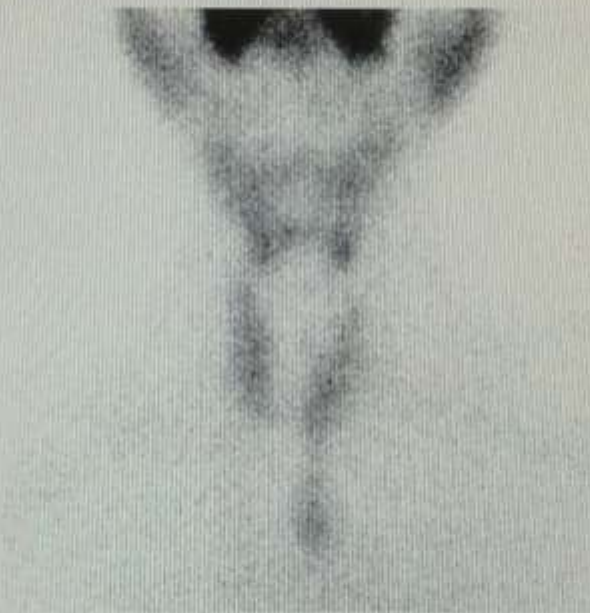
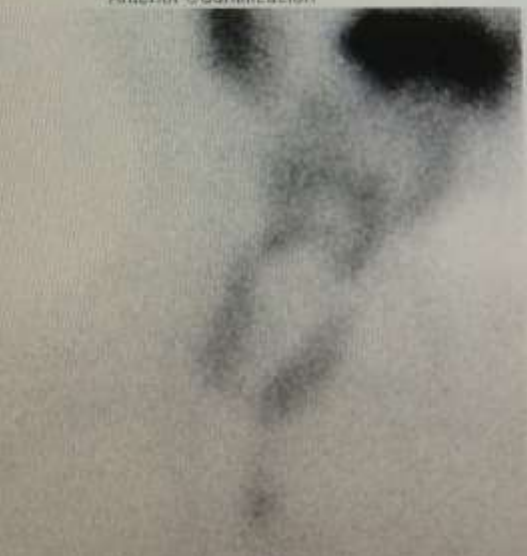- Gammagrafía de Tiroides con aparente tejido tiroideo a nivel de mediastino, se sugiere correlacionar con TAC, Ecografía.

17 de Marzo 2015

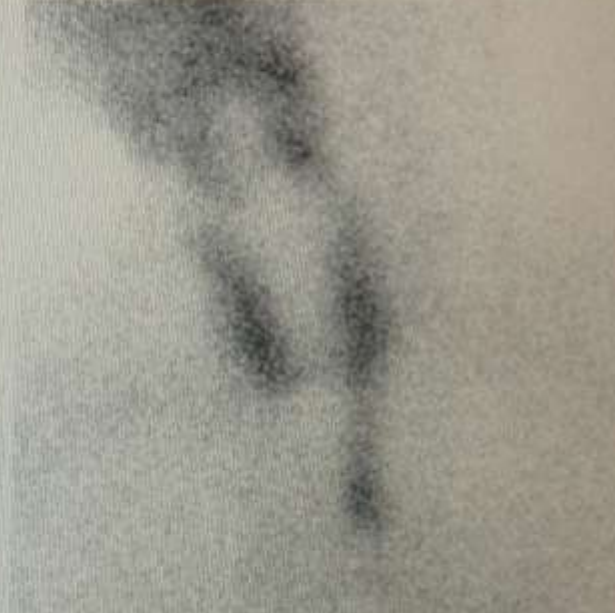GAMMAGRAFIA TIROIDEA 99MTC



Anterior Cuantificación



Anterior



OAI

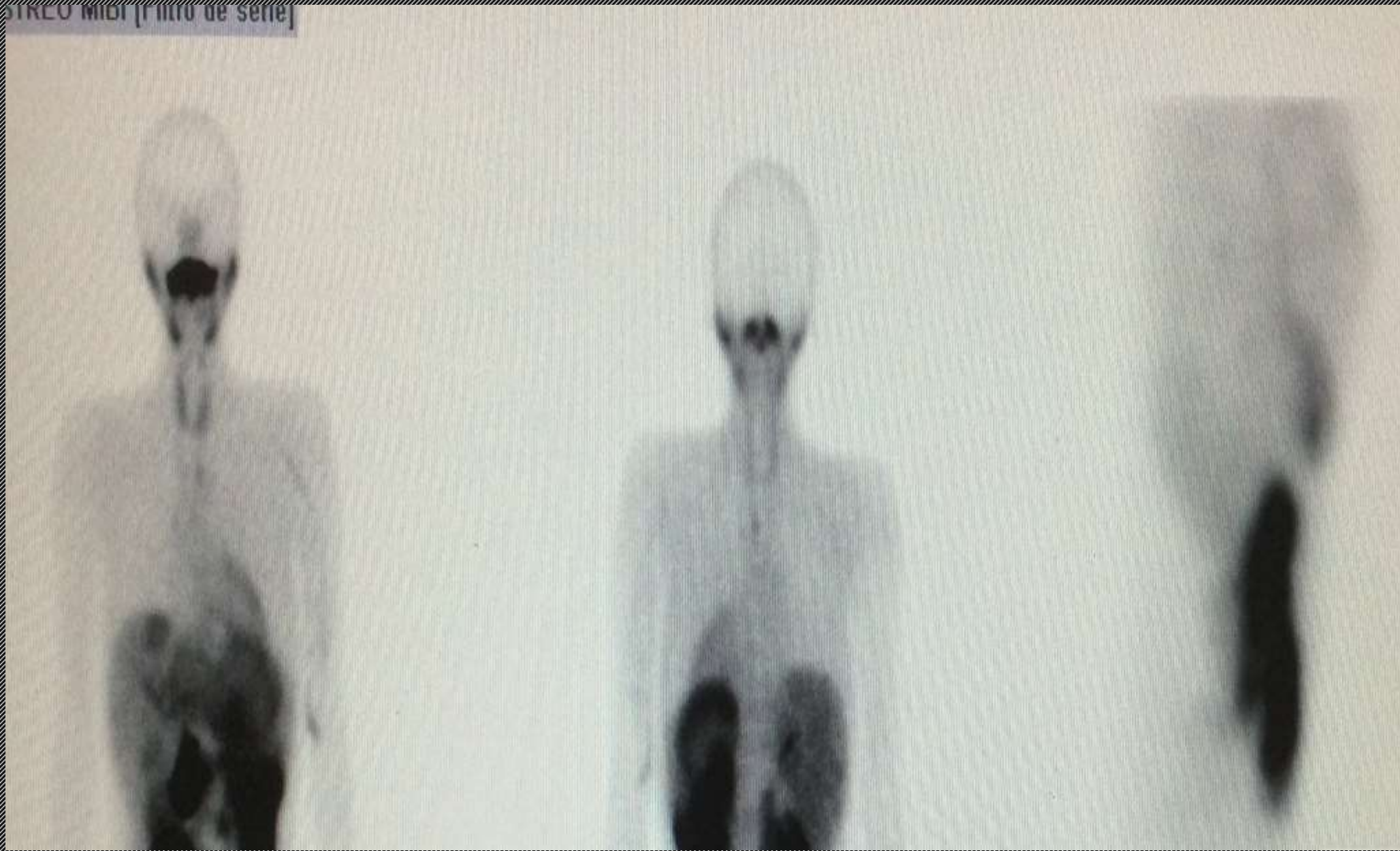


RASTREO DE CUERPO ENTERO CON MIBI-TC 99M

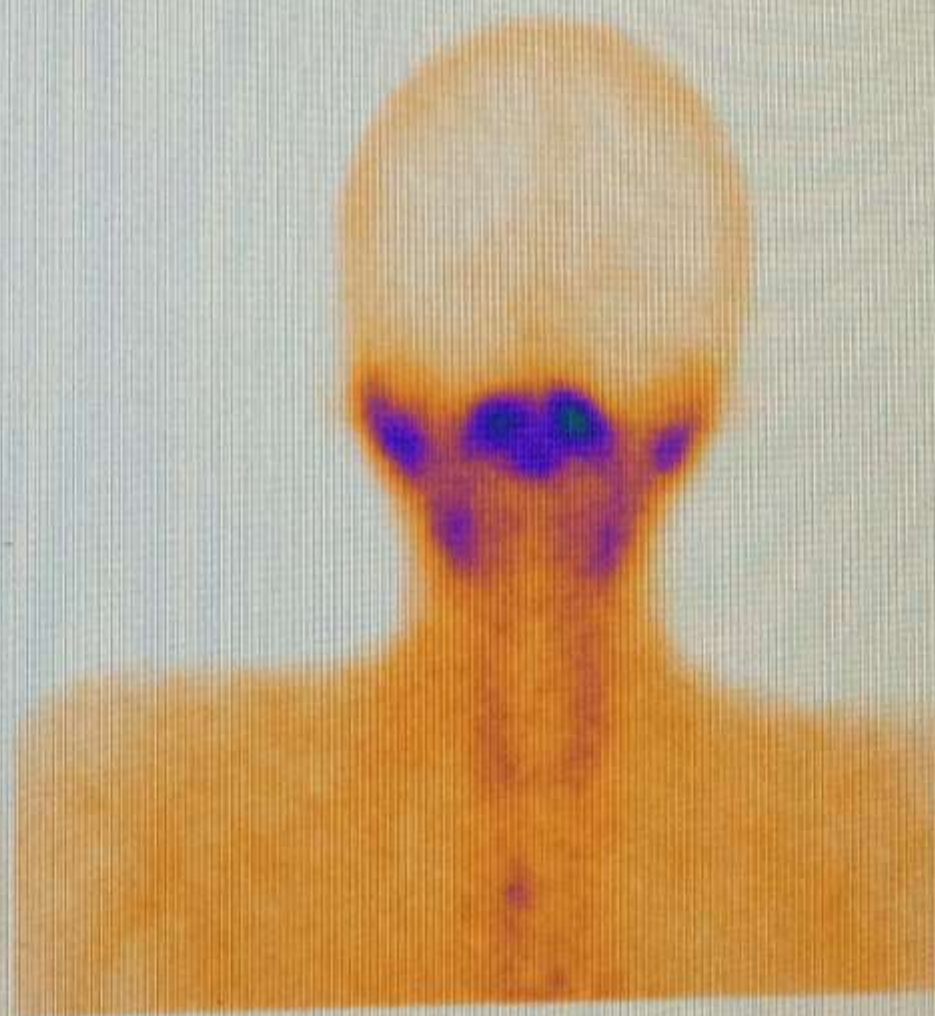
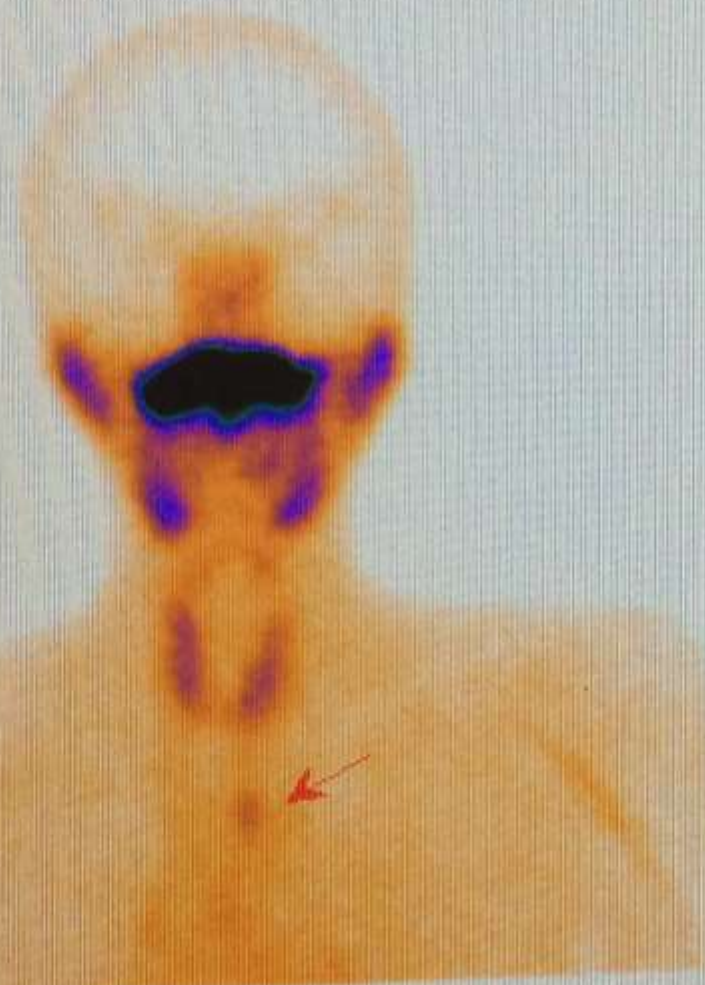
- Rastreo corporal con MIBI con focos a nivel hepático sugerentes de metástasis.
- Área en mediastino de aparente tejido tiroideo, correlacionar con TAC.

17 de Marzo 2015

STEREO MIDI [filmo de serie]



RASTREO MIBI [Filtro de serie]



TAC TÓRAX ABDOMEN PELVIS

- Mediastino: Múltiples adenopatías (>10mm)
- Parénquima Pulmonar: engrosamiento intersticial interlobulillar a nivel de lóbulo superior derecho. Presencia de imagen nodular de 11mm a nivel sub apical derecho.
- Hígado: de bordes regulares, tamaño incrementado con **presencia de tumoraciones hepáticas múltiples, la mayor a nivel del segmento II y III de 7.7 x 13.8cm de diámetro.** Resto sin alteración
- Páncreas: no evaluable por múltiples movimientos de paciente y artefactos.
- Resto de estructuras en límites no patológicos.

TAC ABDOMEN PELVIS

- Hepatomegalia moderada con presencia de formación tumoral extensa en segmentos II y III, con lesiones nodulares satélites sugestivos de proceso neo formativo primario entre otras entidades clínicas.
- Pequeñas imágenes de aspecto quístico de distribución difusa en ambos lóbulos hepáticos.

Abdomen^ABDOMINAL_FAST_SCAN_CC
(Adulto)
CT -
27/03/2015

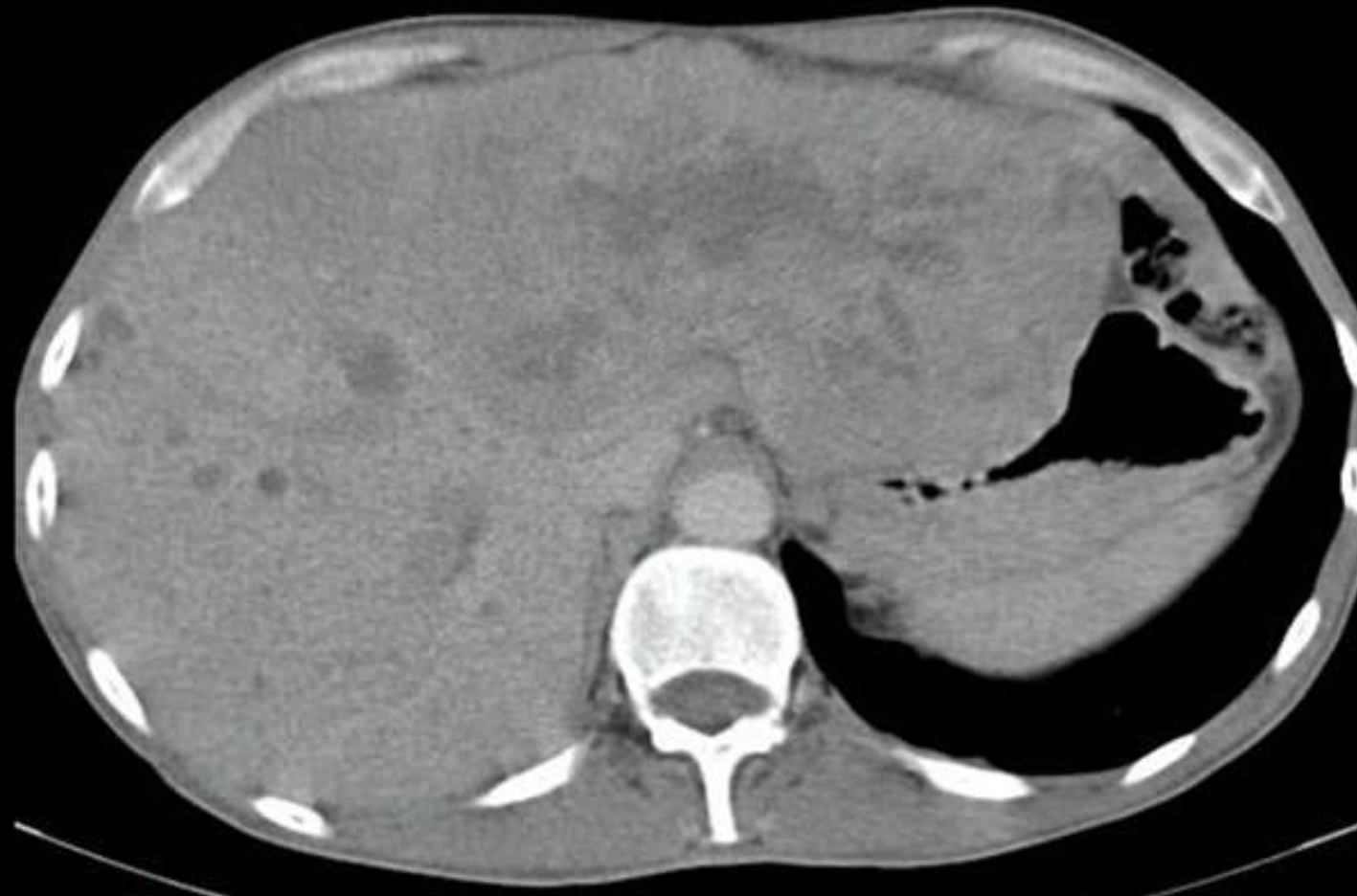

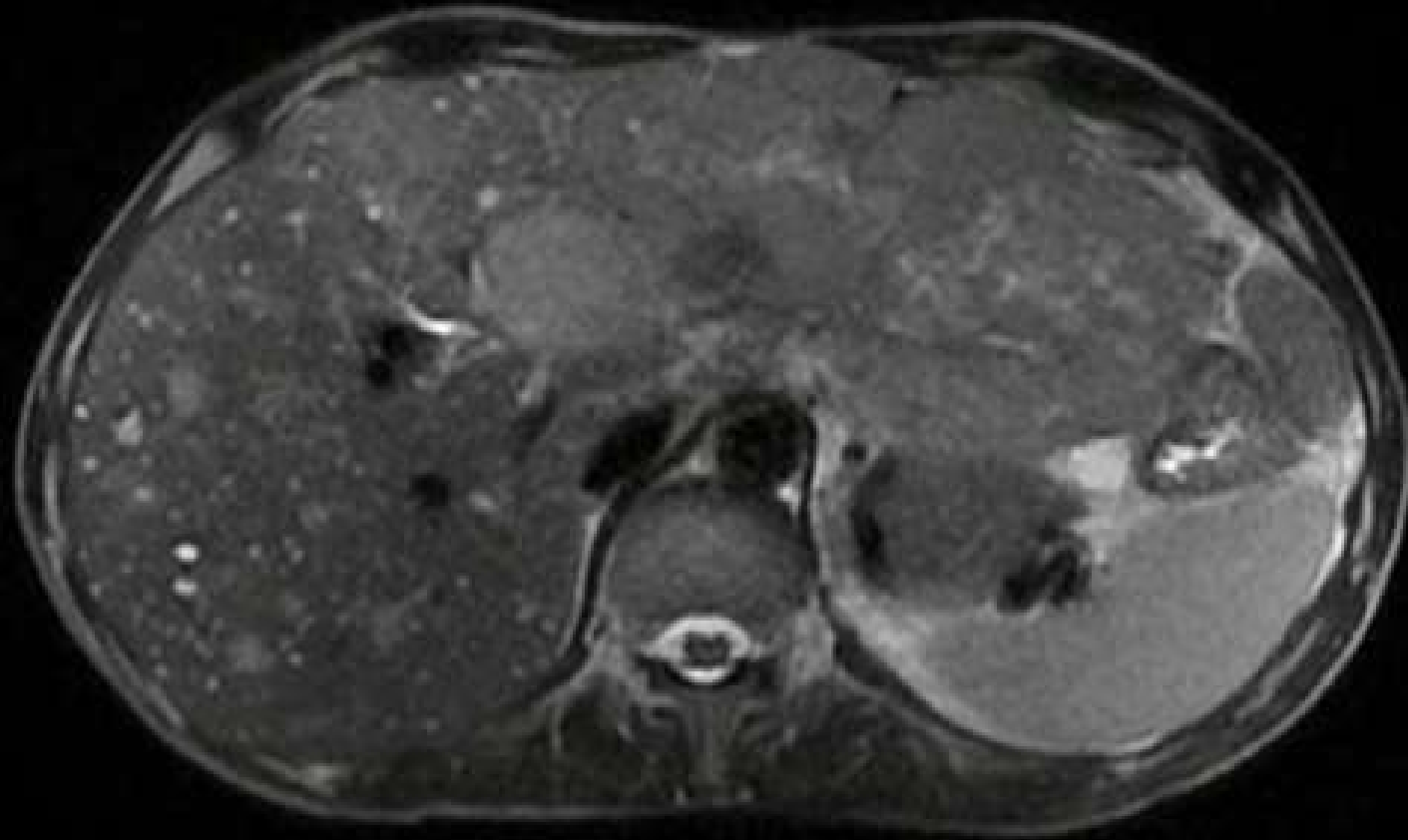
Image 11 of 50

Resonancia Magnética de Abdomen Superior y Colangiorensonancia

- Hígado: Marcado incremento de tamaño. Leve dilatación de la vía biliar intrahepática, prominencia de la vena porta. Presencia de múltiples lesiones sólidas con centro quístico/necrótico y marcada restricción en el estudio de difusión. La mayor 16x11cm
- Páncreas de tamaño prominente a predominio cefálico. Lesión de 8mm en cola, visualizado en fase arterial.

17 Marzo 2015

ABDOMEN COLANGIO RM
MR -
17/03/2015



ABDOMEN COLANGIO RM
MR -
17/03/2015

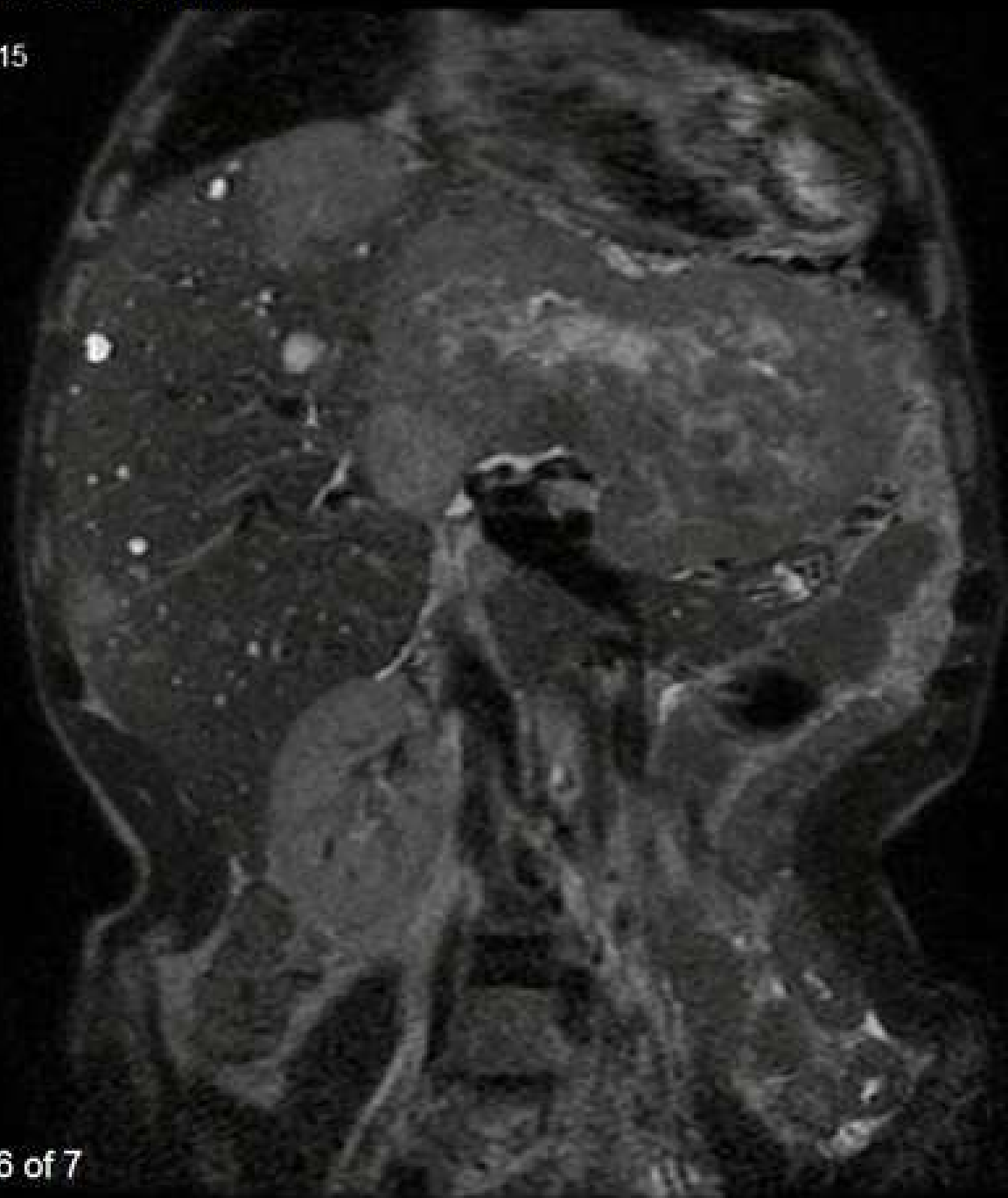


Image 6 of 7



ECOENDOSCOPIA

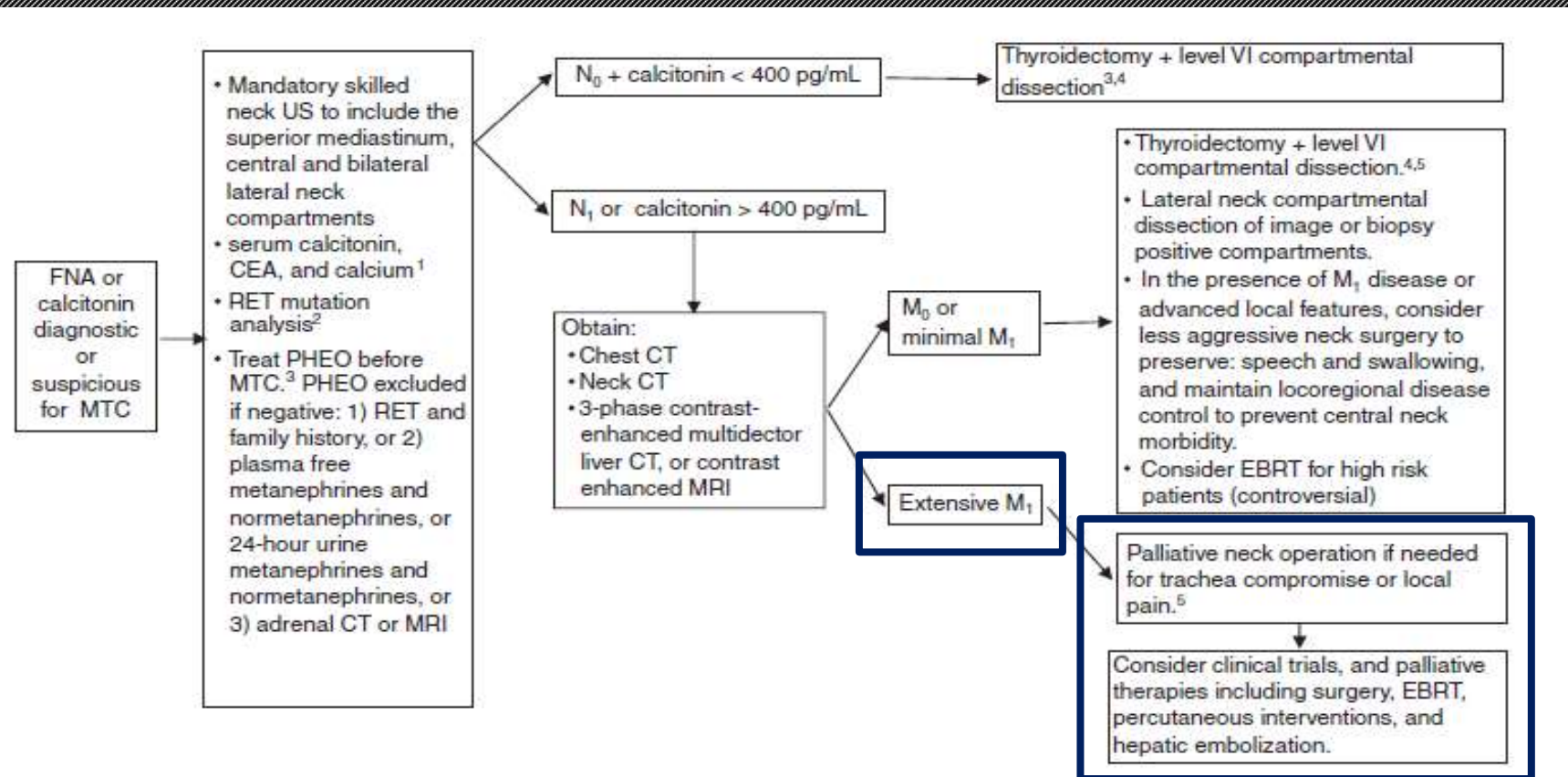
- Papila de tamaño y patrón conservado.
- Vía Biliar NO dilatada
- Páncreas cabeza, cuerpo y cola de tamaño discretamente aumentada. Ecopatrón conservado.
- Hígado se observa GRAN TUMORACION en LHI.
- Mediastino A nivel de la ventana aorto pulmonar y subcarinal se observa **Plastrón Adenomegálico**, se procede a punción aspiración guiada por Ecoendoscopia.

23 Marzo 2015

CITOLOGIA

- Tipo de Muestra : Mediastino
- Resultado:
- Compatible con Carcinoma Medular Tiroides

25 Marzo 2015



¹Treat hyperparathyroidism with 4 gland resection and autograft to heterotopic site, or subtotal parathyroidectomy. Consider cryopreservation.

²Ideally performed with genetics counseling and completed preoperatively.

³PHEO preoperative screening should begin by age 8 years for MEN 2B and mutated *RET* codons 634 and 630; and by age 20 years for other *RET* mutations.

⁴Parathyroid glands resected or devascularized should be autografted in the neck in *RET*-negative, MEN 2B, and FMTC patients, while MEN 2A glands should be autografted to a heterotopic site.

⁵Consider external beam radiation of TNM stage T4 disease to prevent recurrent local disease.

FNA, fine-needle aspiration biopsy.

FIG. 2. Initial diagnosis and therapy of clinically apparent disease.

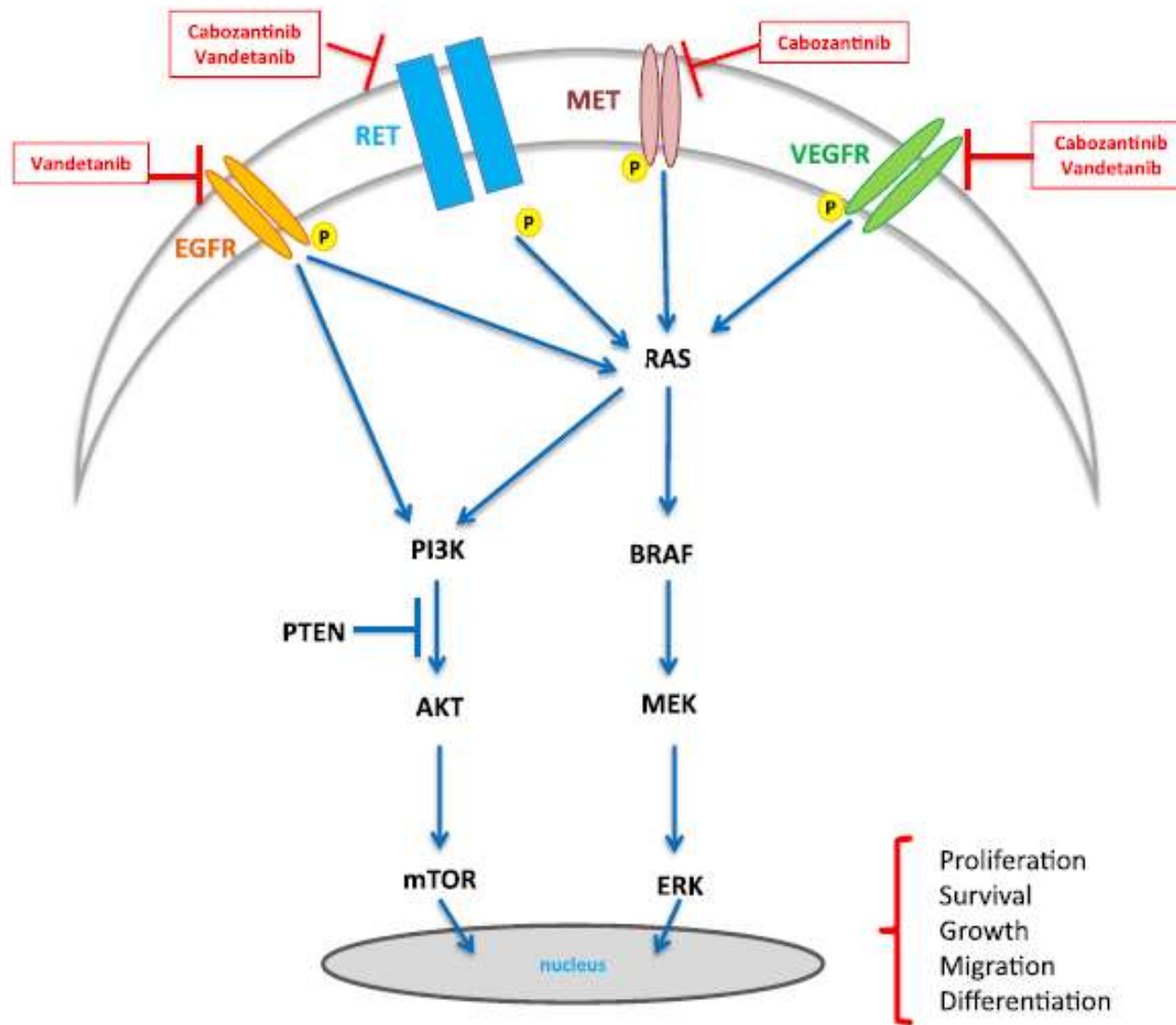


Fig. 1. The MTC receptors and molecular pathways that are targeted by vandetanib and cabozantinib.

CITOLOGIA

LOCALIZACION	HIGADO	HIGADO (IV -VIII)	MEDIASTINO	HIGADO
FECHA	21/11/2014	08/02/2015	25/03/2015	27/03/2015
AG HEPATOCITARIO	-	-	NR	NR
CK7	-	-	NR	NR
CK20	-	-	NR	NR
CROMOGRANINA	+	NR	NR	NR
SINAPTOFISINA	+	+	+	NR
S100	NR	-	-	NR
TTF 1	NR	+	NR	-
Ki 67	NR	NR	NR	60 %
p53	NR	NR	NR	-
CALCITONINA	NR	NR	-	-
CEA	NR	NR	-	-
ROJO CONGO	NR	NR	NR	-
ACL	NR	NR	-	NR
PANQUERATINA	NR	NR	+	NR

TABLE 1. TTF-1 Expression Reported in Thyroid Tumors

Tumor Type	Antibody	n	+ Cases	%	References
Papillary carcinoma	8G7G3/1 MAb	51	50	98.0	18–23,25,27
	PAb	10	10	100	17
Macrofollicular variant of papillary carcinoma	8G7G3/1 MAb	3	3	100	24
Follicular carcinoma	8G7G3/1 MAb	38	34	89.5	19–23,25
	PAb	10	10	100	17
Hürthle cell carcinoma	8G7G3/1 MAb	6	2	33	19
Poorly differentiated (insular) carcinoma	8G7G3/1 MAb	14	13	92.9	19,25
Anaplastic carcinoma	8G7G3/1 MAb	73	10	13.7	19,22,23,25,32
	PAb	4	0	0	17
Medullary carcinoma	8G7G3/1 MAb	67	61	91.0	18–23,25,29,30,31
	PAb	28	23	82.1	17,28
Small cell carcinoma	8G7G3/1 MAb	3	1	33.0	20,21
Mucoepidermoid carcinoma	8G7G3/1 MAb	4	2	50.0	33
Follicular adenoma	8G7G3/1 MAb	34	33	97.1	19,22,25,27
	PAb	6	6	100	17
Oncocytic adenoma	8G7G3/1 MAb	6	5	83.3	19

MAb indicates monoclonal antibody; PAb, polyclonal antibody; TTF-1, thyroid transcription factor-1.

TABLE 2. TTF-1 Expression Reported in Lung Tumors

Tumor Type	Antibody	n	+ Cases	%	References
Adenocarcinoma	8G7G3/1 MAb	2614	2004	76.7	18,21,26,35,37,39-50,52-62,64-70,72,74
	SPT24 MAb	579	471	81.3	51,58,63,68,71-73
	PAb	97	64	66.0	36,86,87,110
Signet-ring cell adenocarcinoma	8G7G3/1 MAb	66	55	83.3	54,62,75-77
Nonmucinous bronchioalveolar carcinoma	8G7G3/1 MAb	175	155	88.6	41,49,54,78-82
Mucinous bronchioalveolar carcinoma	8G7G3/1 MAb	126	30	23.8	41,49,62,78-82
Bronchioloalveolar carcinoma (NOS)	8G7G3/1 MAb	35	30	85.7	35,38
Mucinous (colloid) adenocarcinoma	8G7G3/1 MAb	13	10	77	77
Adenocarcinoma with enteric differentiation	8G7G3/1 MAb	13	9	69.2	59,83
Small cell carcinoma	8G7G3/1 MAb	524	456	87.0	23,26,39,46,47,53,54,67,82,85,88-97,99-104
	SPT24 MAb	13	11	84.6	98
	PAb	51	48	94.1	86,87
Typical carcinoid tumor	8G7G3/1 MAb	228	81	35.5	22,23,26,39,54,88,93,96,102,105-108
	PAb	8	0	0	86
Atypical carcinoid tumor	8G7G3/1 MAb	75	28	37.3	22,26,39,54,88,93,96,102,106,107
Carcinoid tumor (NOS)	8G7G3/1 MAb	74	24	32.4	53,68,99,102,104
	SPT24 MAb	23	14	60.9	68
Large cell neuroendocrine carcinoma	8G7G3/1 MAb	172	80	46.5	39,44,56,66,88,93,95,99
Tumorlet	8G7G3/1 MAb	49	8	16	93,106
Squamous cell carcinoma	8G7G3/1 MAb	1057	42	4.0	20,26,35,42-47,52-56,63,65-68,70,82,85,94,97,100,111-113,115,117,120,121
	SPT24 MAb	142	23	16.2	63,68,71
	PAb	92	17	18.5	36,86,87,110
Basaloid squamous cell carcinoma	8G7G3/1 MAb	31	0	0	44,65
Lymphoepithelioma-like carcinoma	8G7G3/1 MAb	26	0	0	54,65
Large cell carcinoma	8G7G3/1 MAb	134	53	39.6	20,26,35,43,47,53,99
Sarcomatoid carcinoma	8G7G3/1 MAb	63	19	30.2	65,126-128
Pleomorphic carcinoma	8G7G3/1 MAb	23	0	0	54
	INA	31	10	32.2	129
Alveolar adenoma	8G7G3/1 MAb	5	5	100	137
Pulmonary blastoma	8G7G3/1 MAb	1	1	100	126
	SPT24 MAb	1	1	100	138
Well-differentiated fetal adenocarcinoma	8G7G3/1 MAb	1	1	100	139
Adeno-myoeplithelioma	8G7G3/1 MAb	5	5	100	140
Sclerosing hemangioma	8G7G3/1 MAb	151	143	94.7	54,130-134
Meningothelial-like pulmonary nodules	BGX-397A MAb	4	0	0	136
Pleuropulmonary blastoma	8G7G3/1 MAb	4	0	0	135

MAb indicates monoclonal antibody; NOS, not otherwise specified; PAb, polyclonal antibody; TTF-1, thyroid transcription factor-1.

TABLE 3. TTF-1 Expression Reported in Extrapulmonary Small Cell Carcinomas

Site	Antibody	n	+ Cases	%	References
Skin	8G7G3/1 MAb	171	1	0.6	29,39,89,91,92,102,104,144–146
	SPT24 MAb	38	3	7.9	98,143
	INA	20	1	5.0	147,148
Gastrointestinal tract	8G7G3/1 MAb	15	8	53.3	92
Esophagus	8G7G3/1 MAb	28	16	57.1	91,149,150
Colon	8G7G3/1 MAb	11	2	18.2	91
Liver	8G7G3/1 MAb	1	1	100	151
	INA	1	0	0	152
Pancreas	8G7G3/1 MAb	1	0	0	91
Salivary gland	8G7G3/1 MAb	20	3	15.0	39,91,92,153
Sinonasal	8G7G3/1 MAb	8	0	0	91
Uterine cervix	8G7G3/1 MAb	35	12	34.3	29,39,91,92,101
Endometrium	8G7G3/1 MAb	1	0	0	92
Vagina	8G7G3/1 MAb	5	1	20.0	92,154,155
Ovary, pulmonary type	8G7G3/1 MAb	3	2	66.7	101,156
Ovary, hypercalcemic type	8G7G3/1 MAb	22	0	0	101,157
	INA	2	2	100	159,160
Breast	8G7G3/1 MAb	4	4	100	39,149,158
	INA	2	2	100	159,160
Bladder	8G7G3/1 MAb	65	25	38.5	29,39,92,141,161
Kidney	8G7G3/1 MAb	2	0	0	29,162
Prostate	8G7G3/1 MAb	79	50	63.3	29,39,91,92,142,163
Thyroid	8G7G3/1 MAb	3	1	33	39,91

INA indicates information not available; MAb, monoclonal antibody; TTF-1, thyroid transcription factor-1.

Expression of Thyroid Transcription Factor-1 in the Spectrum of Neuroendocrine Cell Lung Proliferations With Special Interest in Carcinoids

NATHALIE STURM, MD, GIULIO ROSSI, MD, SYLVIE LANTUEJOUL, MD, MAURO PAPOTTI, MD, SOPHIE FRACHON, MD, CHRISTINE CLARAZ, PIERRE-YVES BRICHON, MD, CHRISTIAN BRAMBILLA, MD, AND ELISABETH BRAMBILLA, MD

TABLE 1. TTF-1 Protein Expression in Pure Neuroendocrine Proliferations of the Lung Using Monoclonal Antibody 8G7G3/1

Histologic Class	No. of Cases*	Positive Cases	Staining Score† in Positive Samples	
		Number (%)	Score ≤ 150	Score > 150
NEH	15	0/15 (0)		
Tumorlet	23	0/23 (0)		
TC	27	0/27 (0)		
AC	23	0/23 (0)		
LCNEC	64	31/64 (49)	14	17
SCLC	55	47/55 (85.5)	23	24

*Available cases interpreted with positive internal controls on paraffin or on frozen material.

†Scores: percentage of positive cells multiplied by intensity of staining (1 to 3).

Abbreviations: NEH, neuroendocrine cell hyperplasia; TC, typical carcinoid; AC, atypical carcinoid; LCNEC, large cell neuroendocrine carcinoma; SCLC, small cell lung carcinoma.

WHO 2000 – Tumor NE	WHO 2010 – Neoplasia NE	ENETS 2012
Tumor NE Bien Diferenciado - Comportamiento Incierto	NET G1	< 2 Mitosis / 10hpf Y < 3% Índice Ki67
Carcinoma NE Bien Diferenciado	NET G2	2 – 20 Mitosis / 10hpf O 3 - 20% Índice Ki67
Carcinoma NE Pobremente diferenciado - Célula Pequeña - Célula Grande	NEC G3 - Célula Pequeña - Célula Grande	20 Mitosis / 10hpf O > 20% Índice Ki67

CITOLOGIA

LOCALIZACION	HIGADO	HIGADO (IV -VIII)	MEDIASTINO	HIGADO
FECHA	21/11/2014	08/02/2015	25/03/2015	27/03/2015
AG HEPATOCITARIO	-	-	NR	NR
CK7	-	-	NR	NR
CK20	-	-	NR	NR
CROMOGRANINA	+	NR	NR	NR
SINAPTOFISINA	+	+	+	NR
S100	NR	-	-	NR
TTF 1	NR	+	NR	-
Ki 67	NR	NR	NR	60 %
p53	NR	NR	NR	-
CALCITONINA	NR	NR	-	-
CEA	NR	NR	-	-
ROJO CONGO	NR	NR	NR	-
ACL	NR	NR	-	NR
PANQUERATINA	NR	NR	+	NR

DIAGNÓSTICO

- Cáncer Medular de Tiroides esporádico.
- d/c Carcinoide pulmonar.

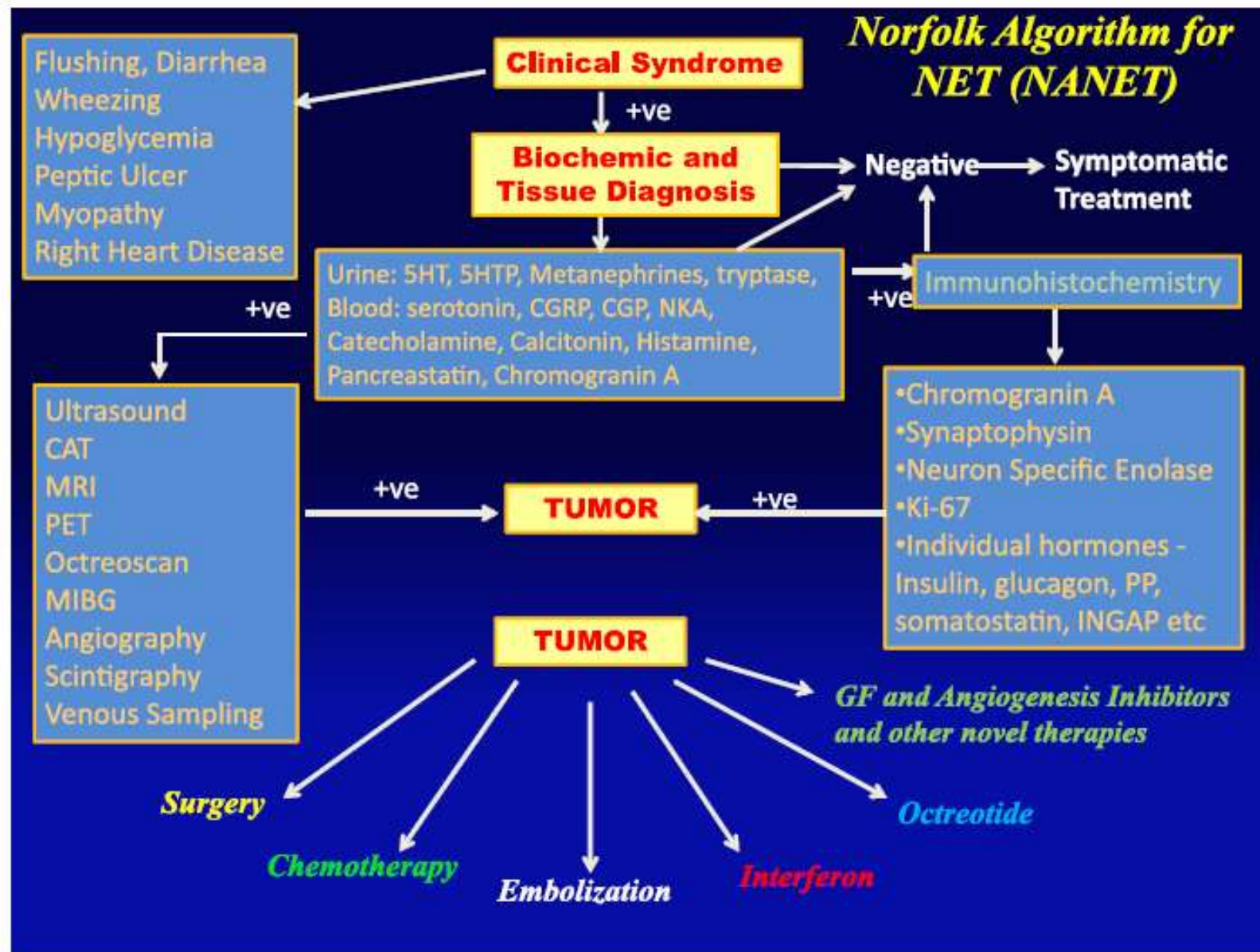


Fig. 6. NANETS algorithm for the evaluation of the patient with a suspected neuroendocrine tumor. (Data from Vinik A. Diffuse hormonal systems and endocrine tumor syndromes. Available at: www.endotext.org.)

GRACIAS
POR SU ATENCIÓN